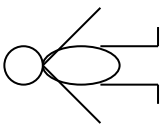
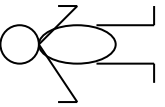
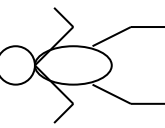
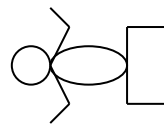
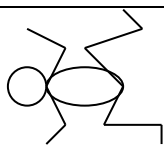
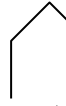

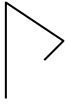




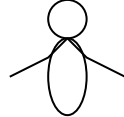
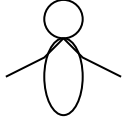
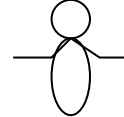
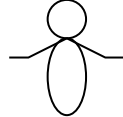
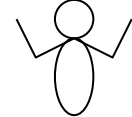




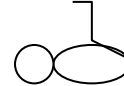


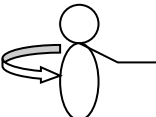
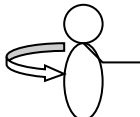
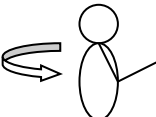
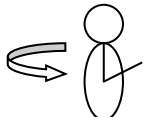
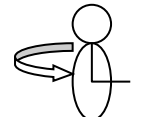
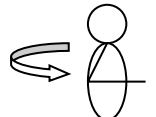


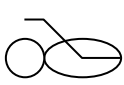





# TEST DE BALLARD POUR EVALUER L'AGE GESTATIONNEL DU NOUVEAU-NÉ

## EVALUATION DE LA MATURITE NEUROMUSCULAIRE

	-1	0	1	2	3	4	5
POSTURE							
ANGLE/ POIGNET	 >90°	 90°	 60°	 45°	 30°	 0°	
RESSAUT/ BRAS							
ANGLE POPLITÉ							
SIGNE DE L'ECHARPE							
ANGLE TALON OREILLE							

## EVALUATION DE LA MATURITÉ PHYSIQUE

PEAU	délicate, fragile transparente	gélatineuse, rouge, translucide	lisse, rose, veines visibles	desquamation ou rash, peu de veines	zones pales, fissures, rares veines	parcheminée, pas de vaisseaux, plis profonds	souple, élastique ridée
LANUGO	absent	éparse	abondant	très fin	partie chauve	sans lanugo	
SURFACE PLANTAIRE	Talon-orteil 40 à 50 mm <40: -2	plus de 50 mm pas de plis	teinte rouge marquée	crêtes plantaires 1/3 ant	crêtes plantaires 2/3 ant	crêtes plantaires sur toute la superficie	
GLANDE MAMAIRE	imperceptible	tout juste perceptible	aréole plane pas de mamelon	aréole en relief mamelon 1-2 mm	aréole surélevée mamelon 3-4 mm	aréole complète mamelon 5-10 mm	
OEIL OREILLE	paupières entrouverte :-1 bien fermée :-2	paupières ouvertes cartilage oreille mou, non élastique	cartilage courbé reprend doucement sa position	cartilage bien formé mais reprend doucement sa position initiale	cartilage bien formé, ferme, reprend immédiatement sa position initiale	cartilage épais et rigide	
GENITAL MALE	scrotum lisse	scrotum vide, peu ridé	testicules dans le canal quelques rides	testicules descendus peu de rides	testicules en position normale bien ridé	testicules pendulaires rides profondes	
GENITAL FEMELLE	clitoris proéminent, grandes lèvres planes	clitoris proéminent apparition petites lèvres	clitoris proéminent petites lèvres formées	petites et grandes lèvres en relief	grandes lèvres bien formées et petites lèvres bien formées	grandes lèvres couvrant le clitoris et les petites lèvres	

SCORE	-10	-5	0	5	10	15	20	25	30	35	40	45	50
SEMAINES	20	22	24	26	28	30	32	34	36	38	40	42	44